

Meet the HHT Care Team



Manjusha Kumar, MD
Pediatric Hematologist



Charles Nakar, MD
Pediatric Hematologist



Angeli Rampersad, MD
Pediatric Hematologist



Magdalena Lewandowska, MD
Adult Hematologist



Anthony Betbadal, MD
Adult Hematologist



Brandon Hardesty, MD
Adult Hematologist

HHT Clinic Information

8:00 a.m. - 4:30 p.m., Monday through Friday

Indiana Hemophilia & Thrombosis Center
8326 Naab Road
Indianapolis, IN 46260

Please visit us online at www.ihtc.org/hht-clinic and to access our *Patient Portal*

HHT referrals

To make a referral or an appointment at the HHT Clinic, please contact IHTC's HHT Clinic Coordinator. **Genetic counseling is available.**

Direct: 317.871.0000

Toll Free: 1.877.256.8837

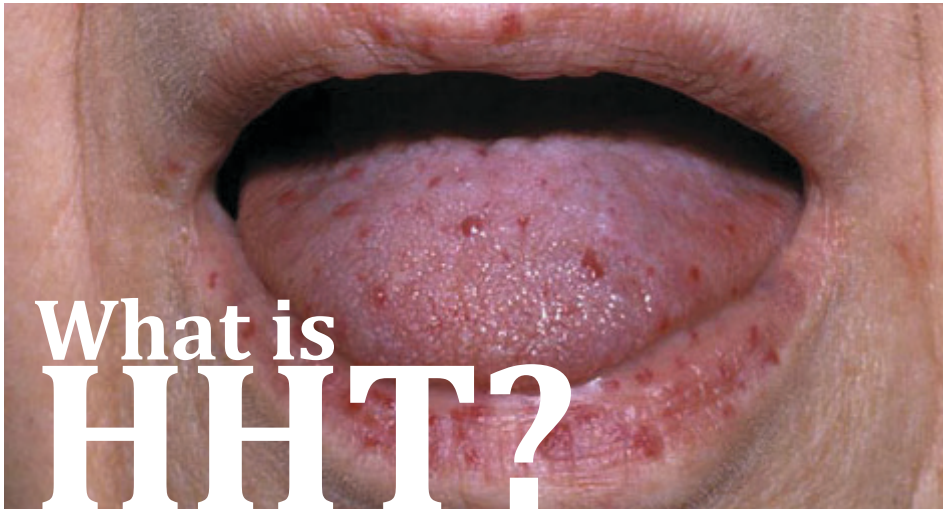Fax: 317.871.0010



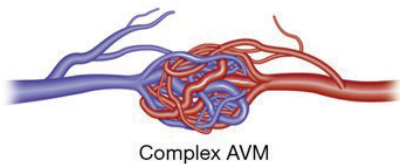
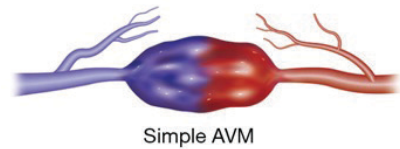
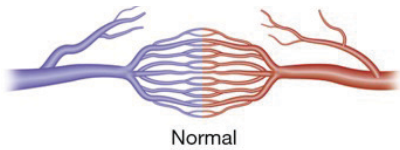
Hereditary Hemorrhagic Telangiectasia: HHT Center

Providing comprehensive, coordinated care





Hereditary Hemorrhagic Telangiectasia (HHT), also known as Osler-Weber-Rendu Syndrome, is an autosomal dominant genetic disorder resulting in abnormal formation of blood vessels; 90% of people with HHT are unaware they have it.



HHT affects approximately 1 in 5,000 people, and males and females from all racial and ethnic groups are affected equally. Most often individuals will present with nosebleeds or visible red spots (telangiectasias) on the skin. Patients can also develop arteriovenous malformations (AVMs) in various internal organs. AVMs may rupture with bleeding in vital organs, such as lungs, intestines, brain or spine. Although telangiectasias or AVMs cannot be prevented, they can be treated to avoid complications of bleeding and anemia. Family members can be screened to prevent life-threatening bleeding.

Symptoms of HHT

Nosebleeds are the most common symptom of HHT, caused by telangiectasias on the inner surface of the nasal mucosa. The average onset is 12 years of age.

- Caused by nasal telangiectasias that are typically identifiable on examination
- Most common symptom of HHT, affecting nearly 90% before age forty
- Can present at any age from early childhood through adulthood
- Can occur spontaneously and may be recurrent
- Frequency and severity of the nosebleeds vary

Skin Telangiectasias are malformations of blood vessels that present as small red dots, and are commonly found on the lips, tongue, face and hands.

A common sign of HHT is skin and mucosal telangiectasia

- Presents as small red/purple pinpoint spots with numbers increasing with age
- May not be visible or easily identified until someone has reached their thirties or forties

Arteriovenous Malformation (AVM) are abnormal communications between arteries and veins. They are commonly found in the lungs, brain and liver.

- Result of abnormal blood vessels connecting arteries directly to veins
- Can be present in lungs, intestines, or brain, and rarely spine
- Can present with serious or life-threatening bleeding

Iron Deficiency Anemia is often present due to blood loss from nosebleeds and gastrointestinal AVMs.

About the IHTC HHT Center

At the IHTC HHT Center, we have an integrated team of healthcare providers with special knowledge of, and interest in HHT. A multidisciplinary approach is used for screening, diagnosis and management.

- Pediatric and adult hematologists with specific knowledge of HHT provide care for patients and their family members
- Genetic counseling and testing
- Screening for at-risk relatives
- Management of complications such as nosebleeds and anemia
- Access to onsite expert multidisciplinary team as needed: physical therapy, dietary, dental hygiene, social work, and academic/career counseling
- Access to referral and care coordination with other specialists such as cardiology, pulmonology, neurology, gastroenterology, and interventional radiology

Image: "hereditary-hemorrhagic-telangiectasia-62558.jpg". Copyright © 2019 OMICS International – Open Access Publisher. Reproduced under Creative Commons Attribution 4.0 International (CC BY 4.0). Accessed May 6, 2019 at: <https://www.omicsonline.org/italy/hereditary-hemorrhagic-telangiectasia-peer-reviewed-pdf-ppt-articles/>.

Illustration: Chamarthy MR et al. Pulmonary arteriovenous malformations: endovascular therapy. Cardiovascular Diagnosis and Therapy 2018; 8(3): 338-349. Cardiovascular diagnosis and therapy by AME Publishing Company. Reproduced with permission of AME Publishing Company in the format Brochure/Promotional Materials via Copyright Clearance Center.